

Diagnosis and Management of Hepatic Encephalopathy

This is a PDF version of the following document:

Module 3: [Management of Cirrhosis-Related Complications](#)

Lesson 4: [Diagnosis and Management of Hepatic Encephalopathy](#)

You can always find the most up-to-date version of this document at

<https://www.hepatitisC.uw.edu/go/management-cirrhosis-related-complications/hepatic-encephalopathy-diagnosis-management/core-concept/all>.

Background

Hepatic encephalopathy describes a broad range of neuropsychiatric abnormalities caused by advanced hepatic insufficiency or portosystemic shunting.[1,2,3] The likelihood of developing hepatic encephalopathy correlates with the severity of the liver disease. Hepatic encephalopathy is broadly classified as either overt hepatic encephalopathy (neurologic and neuropsychiatric abnormalities detected with bedside examination and bedside tests) or minimal hepatic encephalopathy (normal mental status and normal neurologic examination in conjunction with abnormalities on psychometric testing).[4] Overt hepatic encephalopathy will occur in approximately 30 to 40% of individuals with cirrhosis at some point during their illness.[2] Individuals with cirrhosis who undergo transjugular intrahepatic portosystemic shunts (TIPS) also frequently develop overt hepatic encephalopathy, with an estimated incidence of 10 to 50%.[3,5] This risk may be decreased with newer stent designs and smaller diameter shunts, but the risk is still substantial.[6] Minimal hepatic encephalopathy is estimated to develop in more than 80% of persons with cirrhosis. The onset of hepatic encephalopathy in a person with cirrhosis signals a poor prognosis and reduced survival, especially if liver transplantation is not performed.[7,8,9]

Pathogenesis

Although hepatic encephalopathy is not a single clinical entity and precise details of its pathogenesis remain incompletely understood, there is a consensus that elevated levels of ammonia play a central role in this disorder, primarily by acting as a neurotoxin that generates astrocyte swelling.[1] As part of the normal physiologic process, colonic bacteria and gut mucosal enzymes break down dietary proteins, which results in the release of ammonia from the gut into the portal circulation.[3,4] Normally, the ammonia is converted to urea in the liver. In many persons with liver failure or portosystemic shunting, the ammonia released into the portal circulation does not get adequately eliminated by the liver and it accumulates at high levels in the systemic circulation.[1,4] The circulating ammonia results in substantial levels of ammonia crossing the blood-brain barrier where rapid conversion to glutamine occurs by astrocytes; in the brain, astrocytes are the only cells that convert ammonia to glutamine.[1,4] Within astrocytes, glutamine levels accumulate, acting as an osmolyte to draw water inside the cell, which causes astrocyte swelling. The end result of the high circulating levels of ammonia is cerebral edema and intracranial hypertension.[4] Other factors, such as oxidative stress, neurosteroids, systemic inflammation, increased bile acids, impaired lactate metabolism, and altered blood-brain barrier permeability likely contribute in the process of hepatic encephalopathy.[1,4,10]

Nomenclature

In 1998, a consensus group at the 11th World Congress of Gastroenterology in Vienna proposed a

standardized nomenclature for hepatic encephalopathy based on the type of hepatic abnormality, the severity of the manifestations, and the frequency (episodic or persistent) ([Figure 1](#)).[11] The International Society for Hepatic Encephalopathy and Nitrogen Metabolism (ISHEN) consensus identifies disorientation or asterix as the beginning of overt hepatic encephalopathy (grade II through IV), which consists of neurological and psychiatric abnormalities that can be detected by bedside clinical tests, whereas covert hepatic encephalopathy (minimal and grade 1) can only be distinguished by specific psychometric tests, as these individuals have normal mental and neurological status on clinical examination.[4,12]

Clinical Features

Clinical Manifestations

Individuals with hepatic encephalopathy may present with a wide array of neurologic and psychiatric manifestations, including alterations in intellectual capacity, memory, emotional, behavioral, psychomotor speed, and fine motor skills.[3,4] These can lead to apathy, irritability, decreased energy level, impaired sleep-wake cycle, impaired cognition, diminished consciousness, asterixis, or loss of motor control.[2,3] Although persons with hepatic encephalopathy may develop focal neurologic findings, such as hemiplegia, an alternative cause for a new focal neurologic deficit (e.g., intracerebral hemorrhage) should be investigated further. Often, asterixis can be detected in persons with early to middle stages of hepatic encephalopathy.[2,4] To test for asterixis, the person should extend their arms, dorsiflex their wrists, and hold this position, ideally with eyes closed ([Figure 2](#)).[3] A positive test for asterixis is characterized by an involuntary flapping tremor at the wrist due to abnormal functioning of the motor centers that control the tone of muscles involved with maintaining posture; this tremor can also be seen in the tongue, eyelids, lower extremities.[2,3] If the person is too somnolent to raise his or her hands, then oscillating grip strength is another means to test for asterixis.[5] Parkinsonian-like symptoms, such as rigidity and tremors, can also be present.[2] Persons with severe hepatic encephalopathy can develop somnolence that can progress to coma. When evaluating a person with suspected hepatic encephalopathy, it is important to consider and evaluate other causes of altered mental status.[4]

Diagnosis and Testing

Diagnosis and Severity Rating

Overt hepatic encephalopathy is diagnosed based on clinical findings and by excluding other causes of altered mental status.[2] The most common disorders to consider in the differential diagnosis of overt hepatic encephalopathy are medication-related adverse effects, severe electrolyte disorders (hyponatremia and hypercalcemia), uremia, systemic infection, central nervous system infection, psychiatric disorders, alcohol-related disorders (intoxication, withdrawal, or Wernicke-Korsakoff syndrome), hypoglycemia, hypercapnia, nonconvulsive epilepsy, and intracranial bleeding or stroke.[2,4] As part of the diagnostic process, the clinician should categorize the type and severity of the overt hepatic encephalopathy.[2] For most individuals, the West Haven criteria (or Conn score) is the best known criteria for categorizing the severity of overt hepatic encephalopathy; it grades the severity of the hepatic encephalopathy based on a clinical assessment, with a score ranging from grade 0 (no abnormalities) to grade 4 (coma) (Figure 3). [11,12] The Glasgow Coma Scale, however, may be more useful in persons with severe encephalopathy and a marked alteration in mental status (Figure 4).[2] The diagnosis of minimal hepatic encephalopathy requires specific psychometric testing.[13,14,15]

Laboratory Testing

For persons with known cirrhosis and suspected hepatic encephalopathy, laboratory testing serves an important role in identifying precipitating factors and in excluding alternative causes of altered mentation. Common laboratory testing includes assessment of liver and renal function, electrolytes, glucose, complete blood count (CBC), cultures, and drug screening. Arterial and venous ammonia levels may correlate with the severity of hepatic encephalopathy. When obtaining an ammonia level, the blood sample should be collected without the use of a tourniquet and must be transported on ice to the laboratory and analyzed within 20 minutes of collection to ensure accuracy of the results.[4] In addition, there are many non-hepatic causes of hyperammonemia, such as gastrointestinal bleeding, renal failure, hypovolemia, extensive muscle use, urea cycle disorder, parenteral nutrition, urosepsis, and use of certain medications, such as valproic acid. Although persons with hepatic encephalopathy have elevated serum ammonia levels, the severity of hepatic encephalopathy does not correlate with serum ammonia levels beyond a certain point.[16,17] For all of these reasons, obtaining serum ammonia levels to diagnose hepatic encephalopathy is not recommended, but if the test was ordered and the result was normal, the diagnosis of hepatic encephalopathy should prompt a reevaluation.[2] Serial monitoring of blood ammonia levels may be rarely used to assess the efficacy of treatment, but following clinical symptoms is preferable.[2] Routine ammonia measurements during long-term follow-up of persons with cirrhosis are not recommended.

Imaging

Radiographic brain imaging is typically used to help exclude other causes of altered mentation. Brain computed tomographic (CT) imaging has low sensitivity for detecting early cerebral edema but may help to diagnose intracerebral hemorrhage. Brain magnetic resonance imaging (MRI) can be used to diagnose cerebral edema and other brain abnormalities associated with hepatic encephalopathy. Bilateral and symmetric hyperintensity of the globus pallidus in the basal ganglia on T₁-weighted MRI imaging can be seen in persons with cirrhosis and hepatic encephalopathy, but these findings do not correlate with hepatic encephalopathy grade.[18] This finding is thought to result from excess circulating manganese levels. It is unclear if these MRI changes are associated with hepatic encephalopathy specifically or, instead, may be caused by cirrhosis or portosystemic shunting. Thus, MRI is not used to diagnose or grade hepatic encephalopathy. Other types of imaging can also be used to assess for hepatic encephalopathy precipitating factors, such as chest radiograph to evaluate for infection or bowel abdominal imaging to evaluate for obstruction or ileus. Abdominal CT or MRI may also identify large spontaneous portosystemic shunts, which should be considered in persons with recurrent bouts of overt hepatic encephalopathy despite maximal medical management and in the absence of precipitating factors.

Psychometric Tests

In the absence of obvious physical examination findings of hepatic encephalopathy, neuropsychometric tests can be used to identify disturbances in attention, visuospatial abilities, fine motor skills, and memory. These neuropsychometric tests are necessary to make the diagnosis of minimal hepatic encephalopathy.[19] Unfortunately, most of these tests require special expertise, can be very time-consuming to administer, and may not be widely available for use in the United States, as normative data for the local population is needed. They are also nonspecific as any cause of brain dysfunction can lead to abnormal results. From a practical standpoint, the diagnosis of minimal hepatic encephalopathy is important since it is often associated with impaired driving skills.[20,21] The following summarizes some of the most highly recognized and widely used psychometric tests to diagnose minimal hepatic encephalopathy.[2,14,15,22]

- **Number Connection Test Part A and Part B:** The Number Connection Tests can be quickly and easily administered in the office (or at the bedside) and are the most frequently used psychometric tests, but these tests have limited specificity (Figure 5).[23,24] The number tests can be administered as a stand-alone test or as part of the Portosystemic Encephalopathy (PSE) Syndrome Test or Psychometric Hepatic Encephalopathy Score (PHES). Typically, only Part A is completed, and individuals without hepatic encephalopathy should be able to complete the test in a number of seconds that is less than or equal to their age in years. For example, a 55-year-old person should complete the test in less than 55 seconds.
- **Portosystemic Encephalopathy (PSE) Syndrome Test:** The PSE is a paper-and-pencil battery of approximately 30 different psychometric tests to assess various cognitive domains; the PSE was endorsed by the Working Party at the 1998 World Congress of Gastroenterology in Vienna as the gold standard for the diagnosis of minimal hepatic encephalopathy, but clinically this test has been replaced by more practical tests.[11,24].
- **Psychometric Hepatic Encephalopathy Score (PHES):** The PHES utilizes a subset of five tests taken from the Portosystemic Encephalopathy (PSE) syndrome test.[24] The five tests are: (1) Number Connection Test A, (2) Number Connection Test B, (3) Digit Symbol Test, (4) Serial Dotting Test, and (5) Line Tracing Test.[14,24] This test primarily evaluates attention, visuospatial perception, visuospatial construction, psychomotor speed, and motor accuracy.[14,15]
- **Critical Flicker-Frequency Test (CFF):** The CFF test is defined as the frequency at which flickering light can be perceived as continuous. This method utilizes the Schuhfried Test System to assess visual discrimination and functional efficiency of the cerebral cortex (general arousal), and it is a sensitive and reproducible means of diagnosing minimal hepatic encephalopathy.[25,26] From a practical standpoint, this test has the advantage of not relying on education level, numerics, or literacy.[2] The negative aspects of this test are the requirement to purchase software or services, the need to have specialized equipment, and the lack of validity in persons with red-green color blindness.[2]
- **Stroop Test:** The Stroop Test evaluates selective attention and processing speed by the interference between visual color and a written color name. *EncephalApp Stroop* is a smartphone application that utilizes a smartphone or tablet as a screening tool for minimal hepatic encephalopathy by assessing selective attention and inhibitory responses.[27,28] The test utilizes an “off state” that has neutral stimuli and an “on state” that has incongruent stimuli.
- **Inhibitory Control Test (ICT):** The ICT is a computerized test that evaluates sustained attention and working memory impairment.[29,30] During the ICT, which takes about 15 minutes, subjects see a continuous stream of letters on a computer screen, and they are instructed to hit a button if they see an X followed by a Y; the test utilizes lures (XX or YY) to evaluate the ability of the subject to inhibit the response to the lures.[29,30] The test is scored based on the number of correct responses to targets and the lure rate.[14,31]
- **Repeatable Battery for the Assessment of Neurological Status (RBANS):** The RBANS are computerized psychometric tests (e.g., inhibitory control test) and neurophysiologic tests used to diagnose hepatic encephalopathy in clinical trials.[19,32]
- **Continuous Reaction Time (CRT) Test:** The CRT index test measures the stability of motor reaction times (pressing of a button as a response to auditory stimuli) and requires simple software and

hardware to administer.[[33,34](#)]

- **SCAN Test:** The SCAN Test measures speed and accuracy on a digit recognition memory exam in a computerized format.[[35](#)]

Electroencephalography

Electroencephalography (EEG) can assess for mild hepatic encephalopathy and is more objective than psychometric tests, but it is also nonspecific as it can be affected by other metabolic disturbances. In addition, the EEG may be normal in the early stages of hepatic encephalopathy.[[36](#)] Although this test is noninvasive, it requires special instruments and thus is not commonly used in clinical practice.[[5,36](#)]

Approach to the Management of Hepatic Encephalopathy

Basic Principles of Management

The 2014 AASLD-EASL Practice Guideline on Hepatic Encephalopathy provides recommendations regarding the management of persons with hepatic encephalopathy.[2] The 2014 AASLD-EASL Practice Guideline on Hepatic Encephalopathy recommends treatment of hepatic encephalopathy mainly for persons with overt hepatic encephalopathy.[2] The initial approach to management of acute hepatic encephalopathy should focus on providing supportive care, identifying and treating any precipitating causes, reducing nitrogenous load in the gut, and assessing the need for long-term therapy and liver transplant evaluation.[37] Infections play a particularly important role in precipitating overt hepatic encephalopathy.[38,39] The AASLD-EASL 2014 Practice Guideline on Hepatic Encephalopathy has the following key recommendations for the general principles regarding prevention and management of episodic overt hepatic encephalopathy.[2]

- Individuals with an episode of overt hepatic encephalopathy should be actively treated, regardless of whether it occurred spontaneously or was precipitated.
- Primary prophylaxis to prevent an episode of overt hepatic encephalopathy is not required, even after TIPS placement, unless the person with cirrhosis has a known high risk of developing hepatic encephalopathy.
- Initiate secondary prophylaxis against hepatic encephalopathy after an episode of overt hepatic encephalopathy.
- Individuals with liver failure and intractable overt hepatic encephalopathy should be considered for referral for liver transplantation.

Correction of Precipitating Factors

Among the precipitating factors for hepatic encephalopathy, common categories include (1) increased nitrogen load (e.g., gastrointestinal bleed, infection, excess dietary protein), (2) decreased toxin clearance (e.g., hypovolemia, renal failure, constipation, portosystemic shunt, medication noncompliance, acute or chronic liver failure), and (3) altered neurotransmission (e.g., sedating medication, alcohol, hypoxia, hypoglycemia).[37] At least 80% of persons with overt hepatic encephalopathy improve after correction of these precipitating factors.[40] Individuals with grade 3 or higher hepatic encephalopathy may need to be managed in an intensive care or step-down unit, with consideration of intubation for airway protection if needed.[2]

Prevention of Recurrent Hepatic Encephalopathy

Once an individual with encephalopathy demonstrates clinical improvement, management then transitions to the prevention of recurrent hepatic encephalopathy, including reinforcement of compliance with treatment. Therapy for hepatic encephalopathy may be discontinued if a precipitant is identified and appropriately managed in persons who do not have a prior history of overt hepatic encephalopathy. Large dominant spontaneous portosystemic shunts can be embolized in select persons with reasonable liver function, leading to improvement or resolution of overt hepatic encephalopathy.[41,42]

Liver Transplantation Referral

In one retrospective study, it was found that after the first episode of acute hepatic encephalopathy, survival probability drops to less than 50% at 1 year and less than 25% at 3 years.[43] The 2014 AASLD-EASL Practice Guideline on Hepatic Encephalopathy states that overt hepatic encephalopathy by itself is not an indication for liver transplantation, unless associated with hepatic failure, but individuals with severe overt hepatic encephalopathy that is refractory to maximal therapy may be considered for liver transplant referral.[2]

Medical Therapy for Overt Hepatic Encephalopathy

Rapid response to first-line medical therapy supports the diagnosis of hepatic encephalopathy. Most persons with hepatic encephalopathy will respond within 24 to 48 hours of initiation of treatment. Prolongation of symptoms beyond 72 hours despite attempts at treatment should prompt further investigation for other causes of altered mentation. In most situations, the preferred approach is to initiate empiric therapy for hepatic encephalopathy and concomitantly assess for alternative causes of altered mental status and identify precipitating causes. Treatment of acute overt hepatic encephalopathy should be followed by prevention of secondary hepatic encephalopathy. Medical therapy for overt hepatic encephalopathy includes management of episodic hepatic encephalopathy and persistent hepatic encephalopathy ([Figure 6](#)).^[11]

Nonabsorbable Disaccharides

Nonabsorbable disaccharides, such as lactulose or lactitol (not available in the United States), decrease the absorption of ammonia and are considered a first-line treatment for overt hepatic encephalopathy.^[2,10] Lactulose is metabolized by bacteria in the colon to acetic and lactic acid, which reduces colonic pH, decreases survival of urease-producing bacteria in the gut, and facilitates conversion of ammonia (NH₃) to ammonium (NH₄⁺), which is less readily absorbed by the gut.^[3,4] The cathartic effect of these agents also increases fecal nitrogen waste.^[37] Although conflicting data exists on the effectiveness of nonabsorbable disaccharides in the management of hepatic encephalopathy, extensive clinical experience supports use of this therapy.^[44,45,46] Lactulose-related adverse effects include abdominal cramping, flatulence, and diarrhea; excessive doses of lactulose should be avoided as it can cause severe diarrhea that can lead to hypovolemia and electrolyte imbalances.^[4] Of note, in one small study, more of the participants who received polyethylene glycol solution (4L over 4 hours) demonstrated improvement in hepatic encephalopathy scores when compared to those treated with lactulose (3 or more doses of 20 to 30 g over 24 hours), but additional trials are needed to validate these findings.^[47]

- **Initial Dosing:** For acute overt hepatic encephalopathy, the usual starting dose of lactulose is 25 mL (16.7 g) oral syrup every 1 to 2 hours until the person has at least two soft bowel movements.^[2]
- **Maintenance Dosing:** Once the initial effect of lactulose has been achieved, the dose should be adjusted with the goal for the person to have 2 to 3 soft bowel movements per day. This dose typically falls in the range of 10 to 30 g (15 to 45 mL) 2 to 4 times daily.^[4] Lactulose may be continued indefinitely for those with recurrent or persistent hepatic encephalopathy.
- **Management of Persons who Become Comatose:** For comatose individuals, the medication can be administered through a nasogastric tube or rectally as an enema (300 mL in 1 L of water every 6 to 8 hours) until the person is awake enough to start oral therapy.

Antimicrobial Therapy

The goal of antimicrobial therapy is to alter the gut microbiota to create a more favorable microbiome that results in lower endogenous bacterial production of ammonia. Rifaximin is now the preferred antimicrobial agent for the treatment of overt hepatic encephalopathy.

- **Rifaximin:** The oral antimicrobial rifaximin is minimally absorbed (less than 0.4%) and has broad-spectrum activity against gram-positive, gram-negative aerobic, and anaerobic bacteria. Rifaximin causes a favorable change in the gut microbiome, which is believed to augment intestinal barrier function and thereby reduce gut bacterial translocation, systemic inflammation, and cirrhosis-associated immune dysfunction.^[48] Rifaximin (550 mg twice daily) has been shown to be effective in treating hepatic encephalopathy.^[49] In a large, multicenter trial, rifaximin with lactulose maintained remission from hepatic encephalopathy better than lactulose alone and also reduced the number of hospitalizations involving hepatic encephalopathy.^[50] Although rifaximin is usually well tolerated, lactulose should be used as the initial first-line treatment, with rifaximin used as add-on therapy if needed.^[2,51]

- **Neomycin:** The oral antimicrobial neomycin reduces bacterial production of ammonia by inhibiting the enzyme activity of glutaminase, an enzyme that converts glutamine to glutamate and ammonia.[52,53] Oral neomycin (1 to 4 g daily in divided doses) has been shown to have some efficacy for the treatment of hepatic encephalopathy, but this agent is not routinely used because of major potential adverse effects, including ototoxicity and nephrotoxicity.[52,54,55] Neomycin should be considered only as an alternative agent for treating overt hepatic encephalopathy.[2]
- **Metronidazole:** Treatment of overt hepatic encephalopathy with metronidazole targets the treatment of gram-negative anaerobic gut bacteria. These anaerobic bacteria produce urease that hydrolyzes urea to ammonia; decreasing the quantity of anaerobic organisms is postulated to result in decreased ammonia production in the gut.[52] In one study, oral metronidazole 200 mg 4 times daily had similar efficacy as neomycin.[56] Long-term use of metronidazole is associated with potential neurotoxicity. Metronidazole should be considered only as an alternative agent for short-term treatment of overt hepatic encephalopathy.[2]

Nutrition

Around 75% of persons with hepatic encephalopathy have moderate-to-severe protein-calorie malnutrition. Overall, persons with overt hepatic encephalopathy should have a total daily energy intake of 35 to 40 kcal/kg (based on ideal body weight). In addition, persons with hepatic encephalopathy should ideally have multiple, evenly distributed small meals (or liquid nutritional supplements) throughout the day, along with a nighttime snack.[2]

- **Protein Intake:** Dietary protein restriction is not advised for the management of hepatic encephalopathy since loss of skeletal muscle, which metabolizes ammonia, can lead to worsening hepatic encephalopathy.[57,58] For persons with hepatic encephalopathy, the recommended protein intake should be in the range of 1.2 to 1.5 g/kg/day.[2] Some experts have recommended a relative higher intake of vegetable and dairy sources of protein than animal-based protein sources.[2,58,59] In addition, the intake of increased fiber can have benefit, as nonabsorbable vegetable fiber can help promote nitrogen clearance via the stool.[52] Persons with encephalopathy should eat small meals throughout the day with a late-night complex carbohydrate snack to help minimize ammonia production.[58]
- **Branched-Chain Amino Acids:** Individuals with cirrhosis can have an alteration in the balance of amino acids with a relative increase in aromatic amino acids relative to branched-chain amino acids, which is believed to contribute to hepatic encephalopathy.[60,61] The impact of oral branched-chain amino acids on persons with episodic hepatic encephalopathy was summarized in a meta-analysis of 16 randomized clinical trials; this analysis concluded that use of branched-chain amino acids had a beneficial effect on hepatic encephalopathy but did not impact nutritional parameters, quality of life, or mortality.[62] Intravenous branched-chain amino acids have no benefit for persons with hepatic encephalopathy.[63] The use of oral branched-chain amino acids is considered as an alternative (or additional) agent in treatment of persons with hepatic encephalopathy who have not responded to combination therapy with lactulose and rifaximin.[2] There have been few adverse effects associated with branched-chain amino acid supplementation.[64] Nevertheless, the oral formulations of branched-chain amino acids are not used in first-line treatment as they are unpalatable and costly.
- **L-Ornithine-L-Aspartate:** Studies in animals suggest that L-ornithine-L-aspartate can lower blood concentration of ammonia and potentially improve hepatic encephalopathy. One randomized study showed use of intravenous L-ornithine-L-aspartate (20 g/day infused over 4 hours) for 7 days was associated with improved psychometric testing and lower post-prandial levels of ammonia.[65] The use of intravenous L-ornithine-L-aspartate, where it is available, should be considered as an alternative (or additional) agent in treatment of persons with hepatic encephalopathy who have not responded to combination therapy with lactulose and rifaximin.[2] Oral therapy with L-ornithine-L-aspartate is not effective and is not recommended for treatment of hepatic encephalopathy.[2]
- **Zinc:** The element zinc is a cofactor for urea cycle enzymes, and it is an important cofactor in ammonia detoxification; for multiple reasons, it is commonly deficient in persons with cirrhosis.[52] A randomized, open-label trial suggested possible benefit with zinc supplementation in persons with

hepatic encephalopathy, but other studies have shown no benefit.[\[66,67\]](#) Thus, zinc supplementation cannot be routinely recommended in persons with hepatic encephalopathy.

Summary Points

- Overt hepatic encephalopathy consists of neurological and psychiatric abnormalities that can be detected by bedside clinical tests, whereas minimal hepatic encephalopathy can only be distinguished by specific psychometric tests.
- There are many grading scales available for hepatic encephalopathy, including the long-standing West Haven Criteria.
- Diagnosis of overt hepatic encephalopathy requires the exclusion of alternate causes of altered mental status. Serum ammonia levels should not be used as a diagnostic tool or as a means of monitoring response to treatment.
- Treatment of acute overt hepatic encephalopathy should include (1) supportive care, (2) identification and treatment of precipitating factors, (3) reduction of nitrogenous load in the gut, and (4) assessment of need for long-term therapy and liver transplant evaluation.
- Lactulose should be used as initial drug therapy for the treatment of acute hepatic encephalopathy. Rifaximin can be added for those individuals who do not have an adequate response to lactulose.
- Prevention of recurrent hepatic encephalopathy or treatment of persistent hepatic encephalopathy includes drug therapy as well as prevention or avoidance of precipitating factors, including potentially sedating medications.
- Protein restriction should be avoided as a general rule, as it can actually lead to worsening of hepatic encephalopathy. Persons with cirrhosis are advised to consume 1.2 to 1.5 g/kg protein daily.
- Liver transplant evaluation should be considered in appropriate candidates once a diagnosis of overt hepatic encephalopathy is made. Liver transplantation is indicated in persons with liver failure and recurrent intractable overt hepatic encephalopathy.

Citations

1. Liere V, Sandhu G, DeMorrow S. Recent advances in hepatic encephalopathy. *F1000Res*. 2017;6:1637. [\[PubMed Abstract\]](#) -
2. Vilstrup H, Amodio P, Bajaj J, et al. Hepatic encephalopathy in chronic liver disease: 2014 Practice Guideline by the American Association for the Study of Liver Diseases and the European Association for the Study of the Liver. *Hepatology*. 2014;60:715-35. [\[PubMed Abstract\]](#) -
3. Wijdsicks EF. Hepatic Encephalopathy. *N Engl J Med*. 2016;375:1660-1670. [\[PubMed Abstract\]](#) -
4. Prakash R, Mullen KD. Mechanisms, diagnosis and management of hepatic encephalopathy. *Nat Rev Gastroenterol Hepatol*. 2010;7:515-25. [\[PubMed Abstract\]](#) -
5. Bajaj BS. Review article: the modern management of hepatic encephalopathy. *Aliment Pharmacol Ther*. 2010;31:537-47. [\[PubMed Abstract\]](#) -
6. Thornburg B. Hepatic Encephalopathy following Transjugular Intrahepatic Portosystemic Shunt Placement. *Semin Intervent Radiol*. 2023;40:262-8. [\[PubMed Abstract\]](#) -
7. Fichet J, Mercier E, Genée O, et al. Prognosis and 1-year mortality of intensive care unit patients with severe hepatic encephalopathy. *J Crit Care*. 2009;24:364-70. [\[PubMed Abstract\]](#) -
8. García-Martínez R, Simón-Talero M, Córdoba J. Prognostic assessment in patients with hepatic encephalopathy. *Dis Markers*. 2011;31:171-9. [\[PubMed Abstract\]](#) -
9. Tapper EB, Parikh ND. Diagnosis and Management of Cirrhosis and Its Complications: A Review. *JAMA*. 2023;329:1589-1602. [\[PubMed Abstract\]](#) -
10. Hadjihambi A, Arias N, Sheikh M, Jalan R. Hepatic encephalopathy: a critical current review. *Hepatol Int*. 2018;12:135-147. [\[PubMed Abstract\]](#) -
11. Ferenci P, Lockwood A, Mullen K, Tarter R, Weissenborn K, Blei AT. Hepatic encephalopathy--definition, nomenclature, diagnosis, and quantification: final report of the working party at the 11th World Congresses of Gastroenterology, Vienna, 1998. *Hepatology*. 2002;35:716-21. [\[PubMed Abstract\]](#) -
12. Bajaj JS, Cordoba J, Mullen KD, Amodio P, Shawcross DL, Butterworth RF, Morgan MY. Review article: the design of clinical trials in hepatic encephalopathy – an International Society for Hepatic Encephalopathy and Nitrogen Metabolism (ISHEN) consensus statement. *Aliment Pharmacol Ther*. 2011;33:739-47. [\[PubMed Abstract\]](#) -
13. Nabi E, Bajaj JS. Useful tests for hepatic encephalopathy in clinical practice. *Curr Gastroenterol Rep*.

2014;16:362.

[\[PubMed Abstract\]](#) -

14. Weissenborn K. Diagnosis of minimal hepatic encephalopathy. *J Clin Exp Hepatol.* 2015;5:S54-9.
[\[PubMed Abstract\]](#) -
15. Weissenborn K. Psychometric tests for diagnosing minimal hepatic encephalopathy. *Metab Brain Dis.* 2013;28:227-9.
[\[PubMed Abstract\]](#) -
16. Kramer L, Tribl B, Gendo A, Zauner C, Schneider B, Ferenci P, Madl C. Partial pressure of ammonia versus ammonia in hepatic encephalopathy. *Hepatology.* 2000;31:30-4.
[\[PubMed Abstract\]](#) -
17. Ong JP, Aggarwal A, Krieger D, et al. Correlation between ammonia levels and the severity of hepatic encephalopathy. *Am J Med.* 2003;15;114:188-93.
[\[PubMed Abstract\]](#) -
18. Krieger S, Jauss M, Jansen O, Theilmann L, Geissler M, Krieger D. Neuropsychiatric profile and hyperintense globus pallidus on T1-weighted magnetic resonance images in liver cirrhosis. *Gastroenterology.* 1996;111:147-55.
[\[PubMed Abstract\]](#) -
19. Randolph C, Hilsabeck R, Kato A, et al. Neuropsychological assessment of hepatic encephalopathy: ISHEN practice guidelines. *Liver Int.* 2009;29:629-35.
[\[PubMed Abstract\]](#) -
20. Bajaj JS, Saeian K, Schubert CM, et al. Minimal hepatic encephalopathy is associated with motor vehicle crashes: the reality beyond the driving test. *Hepatology.* 2009;50:1175-83.
[\[PubMed Abstract\]](#) -
21. Bajaj JS, Pinkerton SD, Sanyal AJ, Heuman DM. Diagnosis and treatment of minimal hepatic encephalopathy to prevent motor vehicle accidents: a cost-effectiveness analysis. *Hepatology.* 2012;55:1164-71.
[\[PubMed Abstract\]](#) -
22. Tapper EB, Parikh ND, Waljee AK, Volk M, Carlozzi NE, Lok AS. Diagnosis of Minimal Hepatic Encephalopathy: A Systematic Review of Point-of-Care Diagnostic Tests. *Am J Gastroenterol.* 2018;113:529-538.
[\[PubMed Abstract\]](#) -
23. Zeegen R, Drinkwater JE, Dawson AM. Method for measuring cerebral dysfunction in patients with liver disease. *Br Med J.* 1970;2(5710):633-6.
[\[PubMed Abstract\]](#) -
24. Weissenborn K, Ennen JC, Schomerus H, Rückert N, Hecker H. Neuropsychological characterization of hepatic encephalopathy. *J Hepatol.* 2001;34:768-73.
[\[PubMed Abstract\]](#) -
25. Kircheis G, Hilger N, Häussinger D. Value of critical flicker frequency and psychometric hepatic encephalopathy score in diagnosis of low-grade hepatic encephalopathy. *Gastroenterology.* 2014;146:961-9.
[\[PubMed Abstract\]](#) -

26. Kircheis G, Wettstein M, Timmermann L, Schnitzler A, Häussinger D. Critical flicker frequency for quantification of low-grade hepatic encephalopathy. *Hepatology*. 2002;35:357-66.
[\[PubMed Abstract\]](#) -
27. Bajaj JS, Heuman DM, Sterling RK, et al. Validation of EncephalApp, Smartphone-Based Stroop Test, for the Diagnosis of Covert Hepatic Encephalopathy. *Clin Gastroenterol Hepatol*. 2015;13:1828-1835.e1.
[\[PubMed Abstract\]](#) -
28. Bajaj JS, Thacker LR, Heuman DM, et al. The Stroop smartphone application is a short and valid method to screen for minimal hepatic encephalopathy. *Hepatology*. 2013;58:1122-32.
[\[PubMed Abstract\]](#) -
29. Bajaj JS, Hafeezullah M, Franco J, et al. Inhibitory control test for the diagnosis of minimal hepatic encephalopathy. *Gastroenterology*. 2008;135:1591-1600.e1.
[\[PubMed Abstract\]](#) -
30. Bajaj JS, Saeian K, Verber MD, et al. Inhibitory control test is a simple method to diagnose minimal hepatic encephalopathy and predict development of overt hepatic encephalopathy. *Am J Gastroenterol*. 2007;102:754-60.
[\[PubMed Abstract\]](#) -
31. Amodio P, Ridola L, Schiff S, et al. Improving the inhibitory control task to detect minimal hepatic encephalopathy. *Gastroenterology*. 2010;139:510-8, 518.e1-2.
[\[PubMed Abstract\]](#) -
32. Sotil EU, Gottstein J, Ayala E, Randolph C, Blei AT. Impact of preoperative overt hepatic encephalopathy on neurocognitive function after liver transplantation. *Liver Transpl*. 2009;15:184-92.
[\[PubMed Abstract\]](#) -
33. Lauridsen MM, Mikkelsen S, Svensson T, et al. The continuous reaction time test for minimal hepatic encephalopathy validated by a randomized controlled multi-modal intervention-A pilot study. *PLoS One*. 2017;12:e0185412.
[\[PubMed Abstract\]](#) -
34. Lauridsen MM, Thiele M, Kimer N, Vilstrup H. The continuous reaction times method for diagnosing, grading, and monitoring minimal/covert hepatic encephalopathy. *Metab Brain Dis*. 2013;28:231-4.
[\[PubMed Abstract\]](#) -
35. Amodio P, Del Piccolo F, Marchetti P, et al. Clinical features and survival of cirrhotic patients with subclinical cognitive alterations detected by the number connection test and computerized psychometric tests. *Hepatology*. 1999;29:1662-7.
[\[PubMed Abstract\]](#) -
36. Morris H, Kaplan PW, Kane N. Electroencephalography in encephalopathy and encephalitis. *Pract Neurol*. 2024;24:2-10.
[\[PubMed Abstract\]](#) -
37. Khungar V, Poordad F. Hepatic encephalopathy. *Clin Liver Dis*. 2012;16:301-20.
[\[PubMed Abstract\]](#) -
38. Strauss E, da Costa MF. The importance of bacterial infections as precipitating factors of chronic hepatic encephalopathy in cirrhosis. *Hepatogastroenterology*. 1998;45:900-4.
[\[PubMed Abstract\]](#) -

39. Strauss E, Gomes de Sá Ribeiro Mde F. Bacterial infections associated with hepatic encephalopathy: prevalence and outcome. *Ann Hepatol.* 2003;2:41-5.
[\[PubMed Abstract\]](#) -
40. Strauss E, Tramote R, Silva EP, et al. Double-blind randomized clinical trial comparing neomycin and placebo in the treatment of exogenous hepatic encephalopathy. *Hepatogastroenterology.* 1992;39:542-5.
[\[PubMed Abstract\]](#) -
41. Laleman W, Simon-Talero M, Maleux G, et al. Embolization of large spontaneous portosystemic shunts for refractory hepatic encephalopathy: a multicenter survey on safety and efficacy. *Hepatology.* 2013;57:2448-57.
[\[PubMed Abstract\]](#) -
42. Lv Y, Chen H, Luo B, et al. Concurrent large spontaneous portosystemic shunt embolization for the prevention of overt hepatic encephalopathy after TIPS: A randomized controlled trial. *Hepatology.* 2022;76:676-88.
[\[PubMed Abstract\]](#) -
43. Bustamante J, Rimola A, Ventura PJ, Navasa M, Cirera I, Reggiardo V, Rodés J. Prognostic significance of hepatic encephalopathy in patients with cirrhosis. *J Hepatol.* 1999;30:890-5.
[\[PubMed Abstract\]](#) -
44. Sharma BC, Sharma P, Agrawal A, Sarin SK. Secondary prophylaxis of hepatic encephalopathy: an open-label randomized controlled trial of lactulose versus placebo. *Gastroenterology.* 2009;137:885-91, 891.e1.
[\[PubMed Abstract\]](#) -
45. Als-Nielsen B, Gluud LL, Gluud C. Non-absorbable disaccharides for hepatic encephalopathy: a systematic review of randomized trials. *BMJ.* 2004;328:1046.
[\[PubMed Abstract\]](#) -
46. Als-Nielsen B, Koretz RL, Kjaergard LL, Gluud C. Branched-chain amino acids for hepatic encephalopathy. *Cochrane Database Syst Rev.* 2003;(2):CD001939.
[\[PubMed Abstract\]](#) -
47. Rahimi RS, Singal AG, Cuthbert JA, Rockey DC. Lactulose vs polyethylene glycol 3350--electrolyte solution for treatment of overt hepatic encephalopathy: the HELP randomized clinical trial. *JAMA Intern Med.* 2014;174:1727-33.
[\[PubMed Abstract\]](#) -
48. Patel VC, Lee S, McPhail MJW, et al. Rifaximin- α reduces gut-derived inflammation and mucin degradation in cirrhosis and encephalopathy: RIFSYS randomised controlled trial. *J Hepatol.* 2022;76:332-42.
[\[PubMed Abstract\]](#) -
49. Bass NM, Mullen KD, Sanyal A, et al. Rifaximin treatment in hepatic encephalopathy. *N Engl J Med.* 2010;362:1071-81.
[\[PubMed Abstract\]](#) -
50. Sanyal A, Younossi ZM, Bass NM, et al. Randomised clinical trial: rifaximin improves health-related quality of life in cirrhotic patients with hepatic encephalopathy - a double-blind placebo-controlled study. *Aliment Pharmacol Ther.* 2011;34:853-61.
[\[PubMed Abstract\]](#) -

51. Mohammad RA, Regal RE, Alaniz C. Combination therapy for the treatment and prevention of hepatic encephalopathy. *Ann Pharmacother.* 2012;46:1559-63.
[\[PubMed Abstract\]](#) -
52. Jawaro T, Yang A, Dixit D, Bridgeman MB. Management of Hepatic Encephalopathy: A Primer. *Ann Pharmacother.* 2016;50:569-77.
[\[PubMed Abstract\]](#) -
53. Hawkins RA, Jessy J, Mans AM, Chedid A, DeJoseph MR. Neomycin reduces the intestinal production of ammonia from glutamine. *Adv Exp Med Biol.* 1994;368:125-34.
[\[PubMed Abstract\]](#) -
54. Atterbury CE, Maddrey WC, Conn HO. Neomycin-sorbitol and lactulose in the treatment of acute portal-systemic encephalopathy. A controlled, double-blind clinical trial. *Am J Dig Dis.* 1978;23:398-406.
[\[PubMed Abstract\]](#) -
55. Conn HO, Leevy CM, Vlahcevic ZR, Rodgers JB, Maddrey WC, Seeff L, Levy LL. Comparison of lactulose and neomycin in the treatment of chronic portal-systemic encephalopathy. A double blind controlled trial. *Gastroenterology.* 1977;72:573-83.
[\[PubMed Abstract\]](#) -
56. Morgan MH, Read AE, Speller DC. Treatment of hepatic encephalopathy with metronidazole. *Gut.* 1982;23:1-7.
[\[PubMed Abstract\]](#) -
57. Córdoba J, López-Hellín J, Planas M, et al. Normal protein diet for episodic hepatic encephalopathy: results of a randomized study. *J Hepatol.* 2004;41:38-43.
[\[PubMed Abstract\]](#) -
58. Amodio P, Bemeur C, Butterworth R, et al. The nutritional management of hepatic encephalopathy in patients with cirrhosis: International Society for Hepatic Encephalopathy and Nitrogen Metabolism Consensus. *Hepatology.* 2013;58:325-36.
[\[PubMed Abstract\]](#) -
59. Chadalavada R, Sappati Biyyani RS, Maxwell, J, Mullen K. Nutrition in hepatic encephalopathy. *Nutr Clin Pract.* 2010;25:257-64.
[\[PubMed Abstract\]](#) -
60. Cascino A, Cangiano C, Calcaterra V, Rossi-Fanelli F, Capocaccia L. Plasma amino acids imbalance in patients with liver disease. *Am J Dig Dis.* 1978;23:591-8.
[\[PubMed Abstract\]](#) -
61. Morgan MY, Marshall AW, Milsom JP, Sherlock S. Plasma amino-acid patterns in liver disease. *Gut.* 1982;23:362-70.
[\[PubMed Abstract\]](#) -
62. Gluud LL, Dam G, Les I, et al. Branched-chain amino acids for people with hepatic encephalopathy. *Cochrane Database Syst Rev.* 2017;5:CD001939.
[\[PubMed Abstract\]](#) -
63. Watanabe A, Takesue A, Higashi T, Nagashima N. Serum amino acids in hepatic encephalopathy--effects of branched chain amino acid infusion on serum aminogram. *Acta Hepatogastroenterol (Stuttg).* 1979;26:346-57.

[\[PubMed Abstract\]](#) -

64. Swansson WD, Anderson BM, Yeoh SW, Lewis DJ. Management of minimal and overt hepatic encephalopathy with branched-chain amino acids: a review of the evidence. *Eur J Gastroenterol Hepatol.* 2023;35:812-21.
[\[PubMed Abstract\]](#) -
65. Kircheis G, Nilius R, Held C, et al. Therapeutic efficacy of L-ornithine-L-aspartate infusions in patients with cirrhosis and hepatic encephalopathy: results of a placebo-controlled, double-blind study. *Hepatology.* 1997;25:1351-60.
[\[PubMed Abstract\]](#) -
66. Chavez-Tapia NC, Cesar-Arce A, Barrientos-Gutiérrez T, Villegas-López FA, Méndez-Sánchez N, Uribe M. A systematic review and meta-analysis of the use of oral zinc in the treatment of hepatic encephalopathy. *Nutr J.* 2013;12:74.
[\[PubMed Abstract\]](#) -
67. Takuma Y, Nouse K, Makino Y, Hayashi M, Takahashi J. Clinical trial: oral zinc in hepatic encephalopathy. *Aliment Pharmacol Ther.* 2010; 32:1080-90.
[\[PubMed Abstract\]](#) -

References

- Agrawal A, Sharma BC, Sharma P, Sarin SK. Secondary prophylaxis of hepatic encephalopathy in cirrhosis: an open-label, randomized controlled trial of lactulose, probiotics, and no therapy. *Am J Gastroenterol.* 2012;107:1043-50.
[\[PubMed Abstract\]](#) -
- Bajaj JS, Heuman DM, Hylemon PB, et al. Randomised clinical trial: Lactobacillus GG modulates gut microbiome, metabolome and endotoxemia in patients with cirrhosis. *Aliment Pharmacol Ther.* 2014;39:1113-25.
[\[PubMed Abstract\]](#) -
- Bajaj JS, Wade JB, Sanyal AJ. Spectrum of neurocognitive impairment in cirrhosis: Implications for the assessment of hepatic encephalopathy. *Hepatology.* 2009;50:2014-21.
[\[PubMed Abstract\]](#) -
- Blei AT, Córdoba J. Hepatic Encephalopathy. *Am J Gastroenterol.* 2001;96:1968-76.
[\[PubMed Abstract\]](#) -
- Elwir S, Rahimi RS. Hepatic Encephalopathy: An Update on the Pathophysiology and Therapeutic Options. *J Clin Transl Hepatol.* 2017;5:142-151.
[\[PubMed Abstract\]](#) -
- European Association for the Study of the Liver. EASL Clinical Practice Guidelines on the management of hepatic encephalopathy. *J Hepatol.* 2022;77:807-24.
[\[PubMed Abstract\]](#) -
- Hassanein TI, Hilsabeck RC, Perry W. Introduction to the Hepatic Encephalopathy Scoring Algorithm (HESA). *Dig Dis Sci.* 2008;53:529-38.
[\[PubMed Abstract\]](#) -
- Knorr JP, Javed I, Sahni N, Cankurtaran CZ, Ortiz JA. Metronidazole-induced encephalopathy in a

patient with end-stage liver disease. Case Reports Hepatol. 2012;2012:209258.

[\[PubMed Abstract\]](#) -

- Lyon KC, Likar E, Martello JL, Regier M. Retrospective cross-sectional pilot study of rifaximin dosing for the prevention of recurrent hepatic encephalopathy. J Gastroenterol Hepatol. 2017;32:1548-1552. [\[PubMed Abstract\]](#) -
- Mouri S, Tripon S, Rudler M, et al. FOUR score, a reliable score for assessing overt hepatic encephalopathy in cirrhotic patients. Neurocrit Care. 2015;22:251-7. [\[PubMed Abstract\]](#) -
- Rahimi RS, Safadi R, Thabut D, et al. Efficacy and Safety of Ornithine Phenylacetate for Treating Overt Hepatic Encephalopathy in a Randomized Trial. Clin Gastroenterol Hepatol. 2021;19:2626-35.e7. [\[PubMed Abstract\]](#) -
- Safadi R, Rahimi RS, Thabut D, et al. Pharmacokinetics/pharmacodynamics of L-ornithine phenylacetate in overt hepatic encephalopathy and the effect of plasma ammonia concentration reduction on clinical outcomes. Clin Transl Sci. 2022;15:1449-59. [\[PubMed Abstract\]](#) -
- Sharma BC, Sharma P, Lunia MK, Srivastava S, Goyal R, Sarin SK. A randomized, double-blind, controlled trial comparing rifaximin plus lactulose with lactulose alone in treatment of overt hepatic encephalopathy. Am J Gastroenterol. 2013;108:1458-63. [\[PubMed Abstract\]](#) -

Figures

Figure 1 Proposed Nomenclature of Hepatic Encephalopathy

Source: Ferenci P, Lockwood A, Mullen K, Tarter R, Weissenborn K, Blei AT. Hepatic encephalopathy—definition, nomenclature, diagnosis, and quantification: final report of the working party at the 11th World Congresses of Gastroenterology, Vienna, 1998. *Hepatology*. 2002;35:716-21.

Proposed Nomenclature of Hepatic Encephalopathy			
Type	Encephalopathy Associated With	Subcategory	Subdivisions
A	A cute liver failure		
B	Portal-systemic b ypass and no intrinsic hepatocellular disease		
C	C irrhosis and portal hypertension and/or portal-systemic shunts	Episodic	Precipitated Spontaneous ⁺ Recurrent [*]
		Persistent ^{**}	Mild (grade 1) Severe (grades 2 to 4) Treatment-dependent
		Minimal	

⁺Without recognized precipitating factors
^{*}Recurrent = two episodes within one year
^{**}Persistent = cognitive deficits that impact negatively on social and occupational functioning

Figure 2 Testing for Asterixis (Flap Test)

To test for asterixis, the arms are extended and the wrists dorsiflexed. The presence of asterixis is defined as a tremor of the hands with arms extended and wrists held back (dorsiflexed) with failure to hold hands in this position, ideally with eyes closed.

Source: photograph by David H. Spach, MD



Figure 3 West Haven Criteria for Semiquantitative Grading of Mental Status

Source: Ferenci P, Lockwood A, Mullen K, Tarter R, Weissenborn K, Blei AT. Hepatic encephalopathy—definition, nomenclature, diagnosis, and quantification: final report of the working party at the 11th World Congresses of Gastroenterology, Vienna, 1998. *Hepatology*. 2002;35:716-21.

West Haven Criteria for Semi-Quantitative Grading of Mental State	
Grade	Criteria
1	Trivial lack of awareness
	Euphoria or anxiety
	Shortened attention span
	Impaired performance of addition
2	Lethargy or apathy
	Minimal disorientation of time or place
	Subtle personality changes
	Inappropriate behavior
3	Somnolence to semi-stupor but responsive to verbal stimuli
	Confusion
	Gross disorientation
4	Coma (unresponsive to verbal or noxious stimuli)

Figure 4 Glasgow Coma Scale

Source: Teasdale G, Jennett B. Assessment of coma and impaired consciousness. A practical scale. Lancet. 1974;2:81-4.

Glasgow Coma Scale		
Response	Scale	Score
Eye Opening Response	Eyes open spontaneously	4 Points
	Eyes open to verbal command, speech, or shout	3 Points
	Eyes open to pain (not applied to face)	2 Points
	No eye opening	1 Point
Verbal Response	Oriented	5 Points
	Confused conversation, but able to answer questions	4 Points
	Inappropriate responses, words discernible	3 Points
	Incomprehensible sounds or speech	2 Points
	No verbal response	1 Point
Motor Response	Obeys commands for movement	6 Points
	Purposeful movement to painful stimulus	5 Points
	Withdraws from pain	4 Points
	Abnormal (spastic) flexion, decorticate posture	3 Points
	Extensor (rigid) response, decerebrate posture	2 Points
	No motor response	1 Point
Minor Brain Injury = 13-15 points; Moderate Brain Injury = 9-12 points; Severe Brain Injury = 3-8 points		

Figure 5 (Image Series) - Number Connection Test (Image Series) - Figure 5 (Image Series) - Number Connection Test

Image 5A: Number Connection Test: Part A

In the number connection test Part A, the person is instructed to join up the numbers in sequence as fast as possible.

Source: Zeegen R, Drinkwater JE, Dawson AM. Method for measuring cerebral dysfunction in patients with liver disease. Br Med J. 1970;2(5710):633-6.

Number Connection Test: Part A

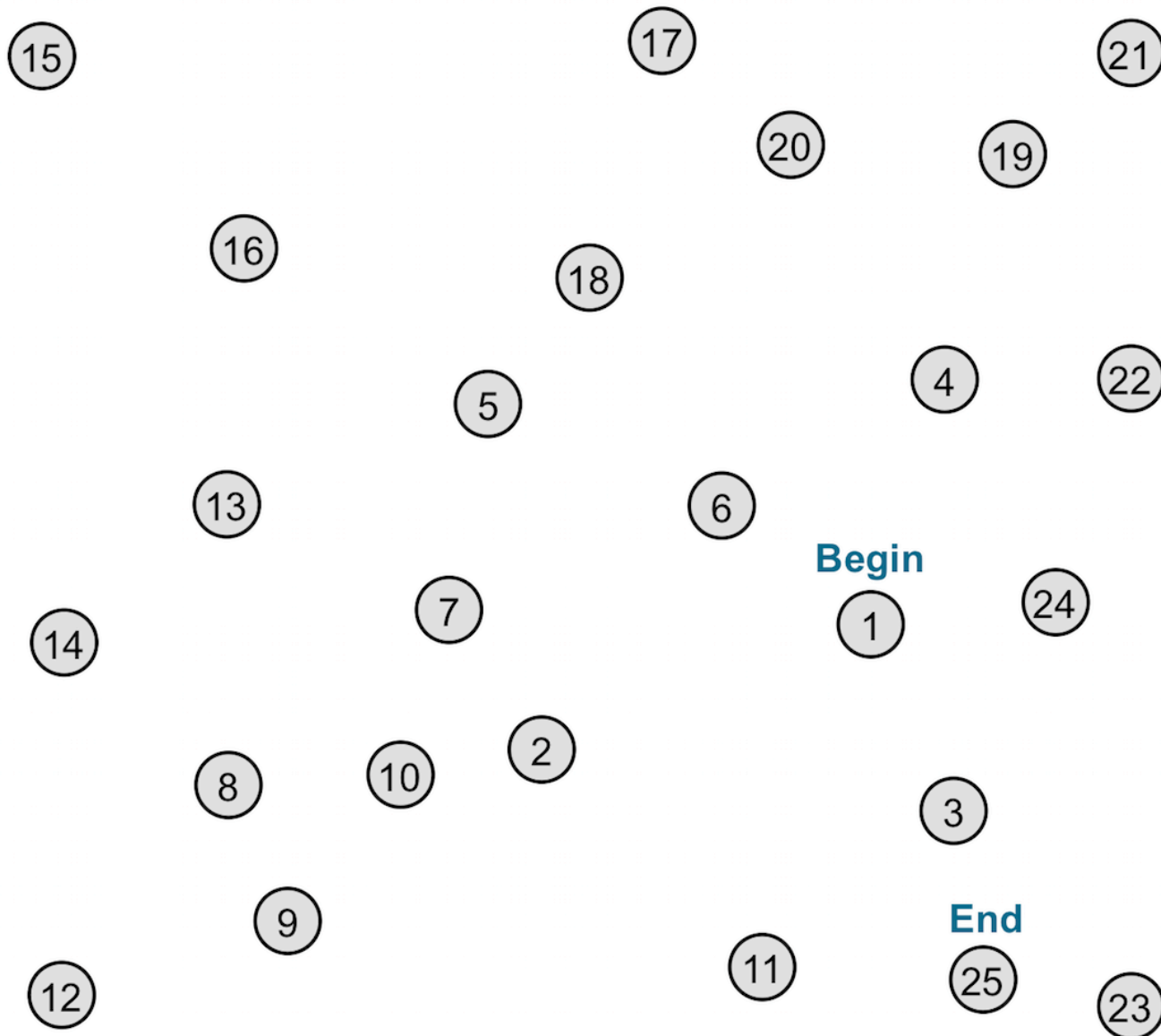


Figure 5 (Image Series) - Number Connection Test
Image 5B: Number Connection Test: Part B

In the number connection test Part B, the person is instructed to join the numbers and the letters alternatively in sequence as fast as possible. For example, connect 1 to A to 2 to B to 3, etc.

Source: Zeegen R, Drinkwater JE, Dawson AM. Method for measuring cerebral dysfunction in patients with liver disease. Br Med J. 1970;2(5710):633-6.

Number Connection Test: Part B

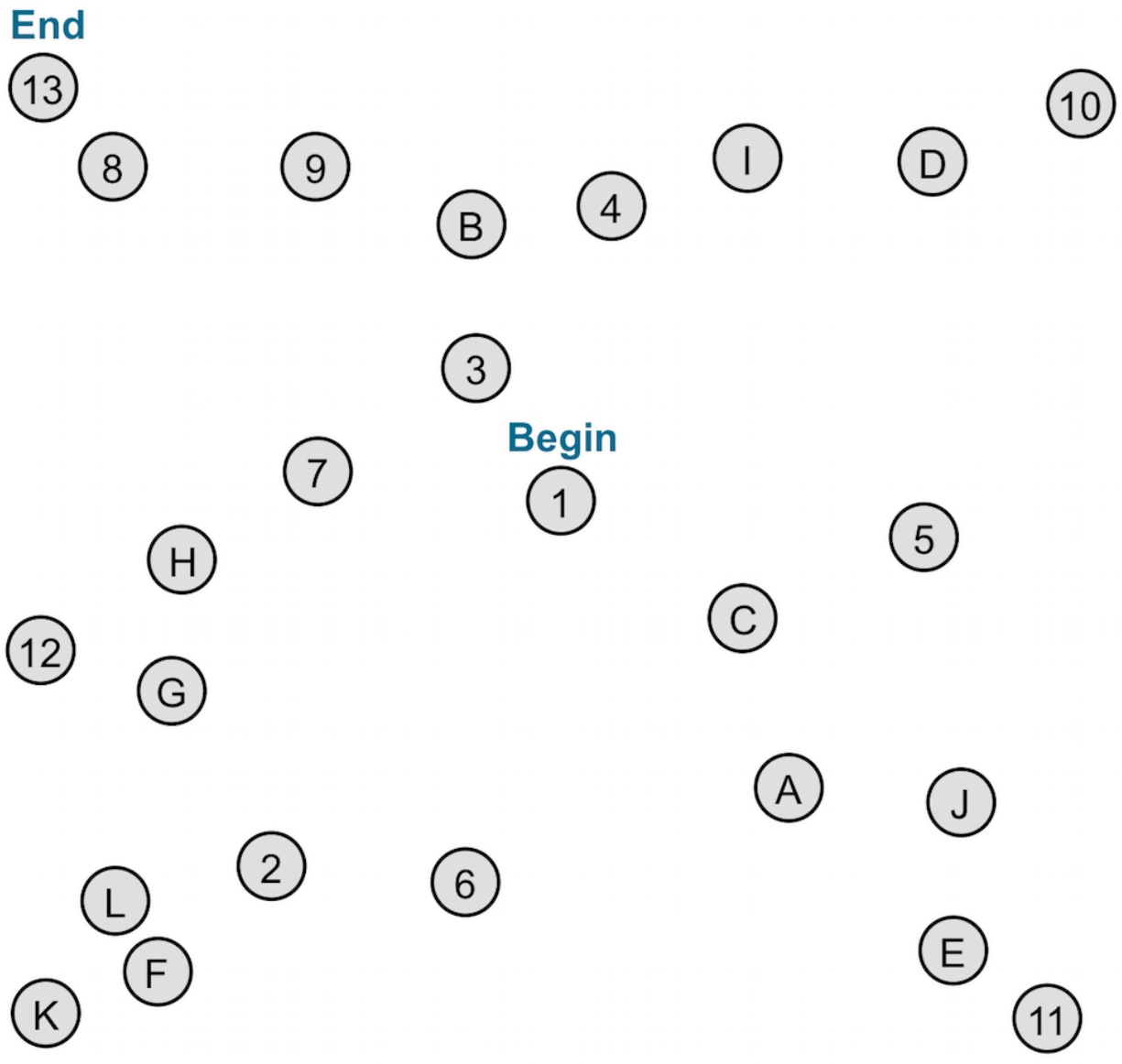


Figure 6 (Image Series) - Therapies for Overt Hepatic Encephalopathy (Image Series) - Figure 6 (Image Series) - Therapies for Overt Hepatic Encephalopathy

Image 6A: Episodic

Source: Ferenci P, Lockwood A, Mullen K, Tarter R, Weissenborn K, Blei AT. Hepatic encephalopathy—definition, nomenclature, diagnosis, and quantification: final report of the working party at the 11th World Congresses of Gastroenterology, Vienna, 1998. *Hepatology*. 2002;35:716-21.

Therapies for Overt Episodic Hepatic Encephalopathy (HE)

1. Supportive care, airway protection
2. Identification and treatment of precipitating causes
3. Lactulose: 10 to 30 g (15-45 mL) orally (per nasogastric tube) every 1 to 2 hours until bowel movement, then 10 to 30 g orally 2 to 4 times daily, titrated to 2 to 3 soft stools daily; or lactulose enema (300 mL in 1 L water) every 6 to 8 hours until able to take oral form of medication
4. Rifaximin: 550 mg PO twice daily
5. Do not limit protein intake
6. Consider need for long term management of HE and liver transplant evaluation

Figure 6 (Image Series) - Therapies for Overt Hepatic Encephalopathy
Image 6B: Persistent

Source: Ferenci P, Lockwood A, Mullen K, Tarter R, Weissenborn K, Blei AT. Hepatic encephalopathy—definition, nomenclature, diagnosis, and quantification: final report of the working party at the 11th World Congresses of Gastroenterology, Vienna, 1998. *Hepatology*. 2002;35:716-21.

Therapies for Overt Persistent Hepatic Encephalopathy (HE)

1. Avoidance and prevention of precipitating factors
2. Lactulose: 10 to 30 g PO 2 to 4 times daily, titrated to 2 to 3 soft stools daily
3. Rifaximin 550 mg PO twice daily
4. Maintain protein intake of 1.0 to 1.5 g/kg daily, over 4 to 6 meals daily with nighttime snack. Vegetable-based protein is preferred for patients with severe persistent HE. Oral branched-chain amino acid supplementation may be considered in those who are intolerant of protein.
5. For severe persistent HE, some patients may be considered for closure or reduction of transhepatic intrahepatic portosystemic shunt (TIPS) diameter or occlusion/embolization of larger portosystemic collaterals (not commonly done in the US)
6. Liver transplant referral for appropriate candidates